

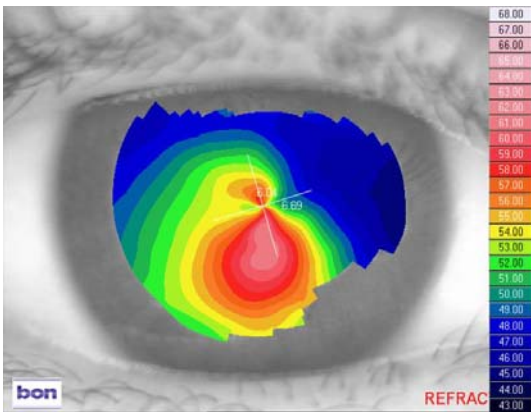
Patient AJ
Female Age: 28 years

History: AJ was diagnosed with keratoconus 8 years previously. RGP lenses had been fitted but were not tolerated as they were extremely uncomfortable and moved excessively, especially on the left eye. Normal soft lenses gave no improvement in vision. The patient is living in Trinidad and the only option offered to her by her ophthalmologist was a full thickness corneal graft for the left eye. However, she could not afford this procedure as she would have to travel overseas due to the fact Trinidad does not have an eye bank.

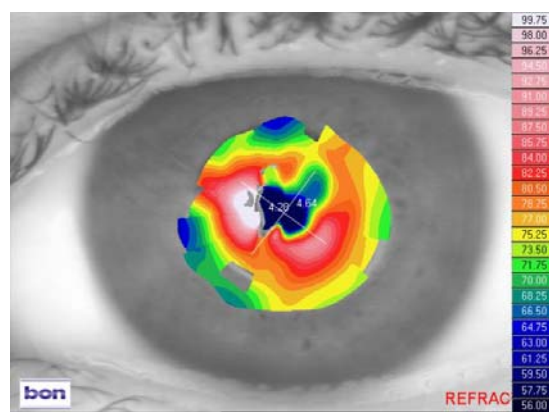
Vision: R: 6/60 L: Hand Movements
Spectacle RX: R: -1.50/-1.00 x 60 VA 6/18-2 L: No spectacle prescription could be obtained
Keratometry: R: 6.19 x 21/6.35 x111 L: No readings possible

The left eye had extensive central scarring due to previous hydrops and exacerbated by attempts at RGP wear. Even though some improvement in acuity could be attained with spectacles in the right eye, she preferred to manage without correction because of the induced distortion and ghosting. The resulting poor vision meant she had a very restricted life and was unable to work.

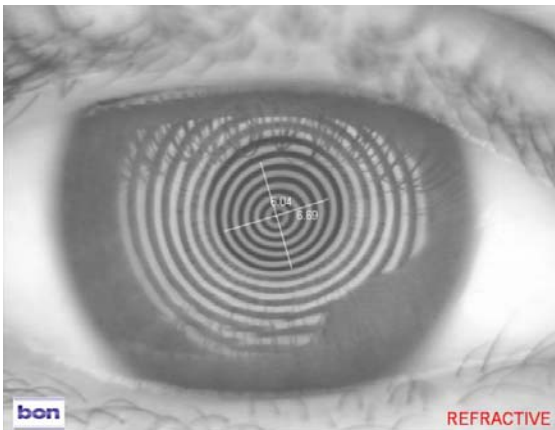
Topography:
RE



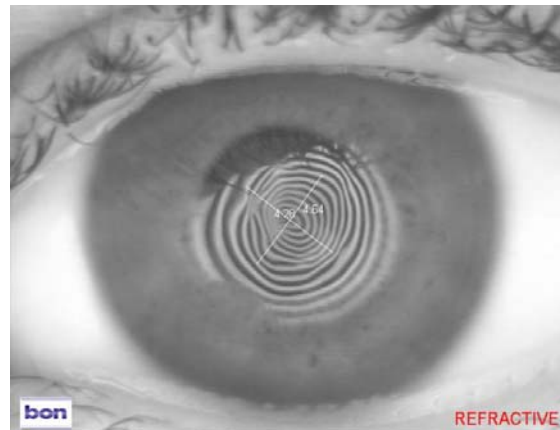
LE



Keratometry:
RE



LE



Keratometry shows the extensive distortion caused by scarring in the left eye.

UK Order Line: 0800 585115 (Freephone)

Tel: +44 (0)1525 381112 Fax: +44 (0)1525 370091

Email: orders@ultravision.co.uk Web: www.ultravision.co.uk; www.siliconehydrogel.co.uk; www.kerasoft3.com

ULTRAVISION INTERNATIONAL LIMITED, COMMERCE WAY, LEIGHTON BUZZARD, BEDFORDSHIRE, LU7 4RW, UNITED KINGDOM

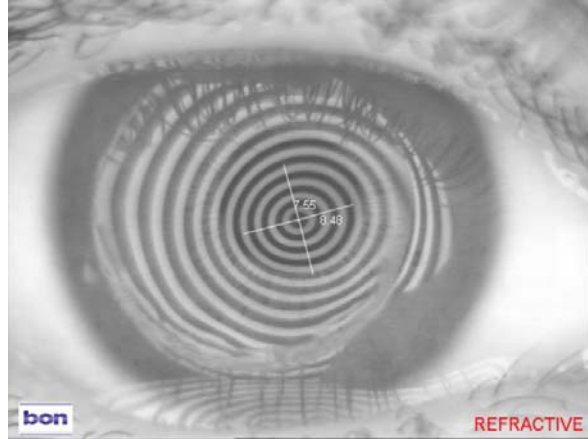
Lens type fitted: KeraSoft®3 by UltraVision produced in Contamac Definitive® Silicone Hydrogel material

R: 8.40/14.00/-3.25/-4.75 x 7 VA 6/6

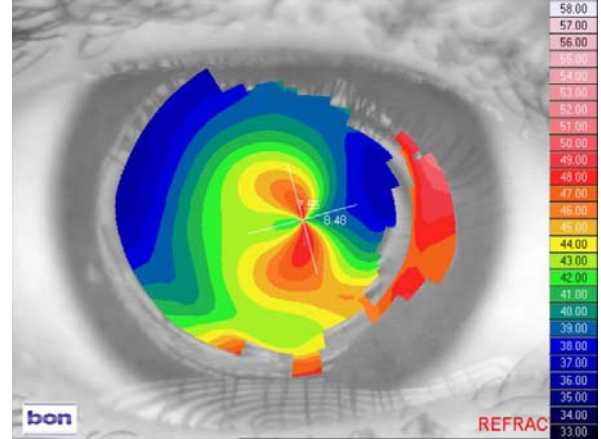
L: 8.40/14.00/-23.00 VA 6/60

Keratotomy and topography of left eye with lens in situ:

LE



LE



The above figures show a great improvement in the anterior optical surface provided by the KeraSoft®3 lens.

Wearing time: With KeraSoft®3, the acuity came up well in the RE and the left now has a useful 6/60. All day wear is possible, even in a tropical climate, and has made a real difference to the patient's life. More importantly, the pressing need for a graft in the LE has now been eliminated and it is something the patient may or may not consider later in life.

UK Order Line: 0800 585115 (Freephone)

Tel: +44 (0)1525 381112 Fax: +44 (0)1525 370091

Email: orders@ultravision.co.uk Web: www.ultravision.co.uk; www.siliconehydrogel.co.uk; www.kerasoft3.com

ULTRAVISION INTERNATIONAL LIMITED, COMMERCE WAY, LEIGHTON BUZZARD, BEDFORDSHIRE, LU7 4RW, UNITED KINGDOM